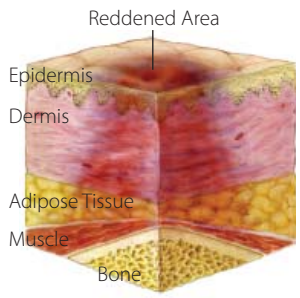


PRESSURE ULCERS

Pressure Ulcer Staging Guide

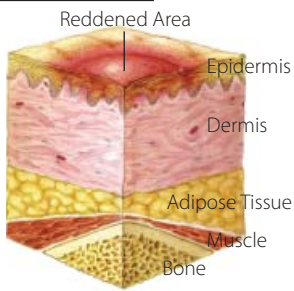
Suspected Deep Tissue Injury:



Purple or maroon localized area of discolored intact skin or blood-filled blister due to damage of underlying soft tissue from pressure and/or shear. The area may be preceded by tissue that is painful, firm, mushy, boggy, warmer, or cooler when compared with adjacent tissue.

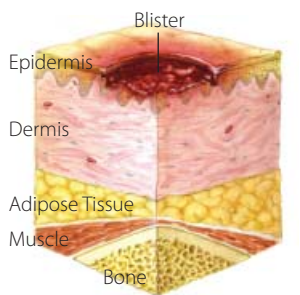
Stage I:

Intact skin with non-blanchable redness of a localized area, usually over a bony prominence. Darkly pigmented skin may not have visible blanching; its color may differ from the surrounding area.



Stage II:

Partial thickness loss of dermis presenting as a shallow open ulcer with a red/pink wound bed, without slough. May also present as an intact or open/ruptured serum-filled blister.

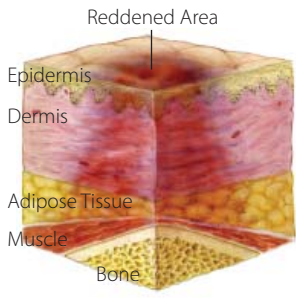


The Medicare Quality Improvement Organization for California
www.hsag.com

PRESSURE ULCERS

Pressure Ulcer Staging Guide

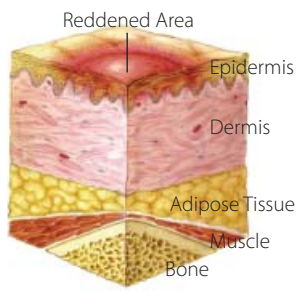
Suspected Deep Tissue Injury:



Purple or maroon localized area of discolored intact skin or blood-filled blister due to damage of underlying soft tissue from pressure and/or shear. The area may be preceded by tissue that is painful, firm, mushy, boggy, warmer, or cooler when compared with adjacent tissue.

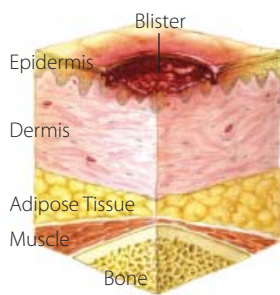
Stage I:

Intact skin with non-blanchable redness of a localized area, usually over a bony prominence. Darkly pigmented skin may not have visible blanching; its color may differ from the surrounding area.



Stage II:

Partial thickness loss of dermis presenting as a shallow open ulcer with a red/pink wound bed, without slough. May also present as an intact or open/ruptured serum-filled blister.

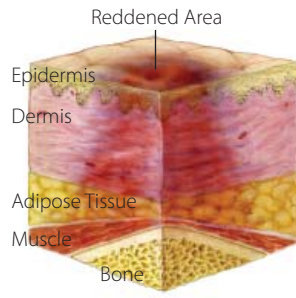


The Medicare Quality Improvement Organization for California
www.hsag.com

PRESSURE ULCERS

Pressure Ulcer Staging Guide

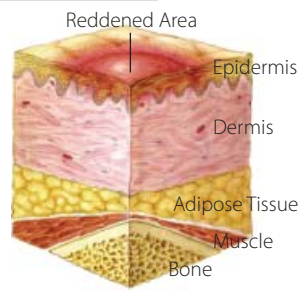
Suspected Deep Tissue Injury:



Purple or maroon localized area of discolored intact skin or blood-filled blister due to damage of underlying soft tissue from pressure and/or shear. The area may be preceded by tissue that is painful, firm, mushy, boggy, warmer, or cooler when compared with adjacent tissue.

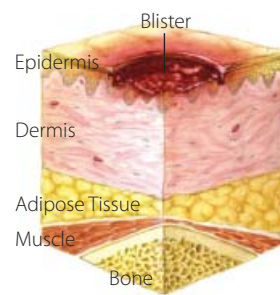
Stage I:

Intact skin with non-blanchable redness of a localized area, usually over a bony prominence. Darkly pigmented skin may not have visible blanching; its color may differ from the surrounding area.



Stage II:

Partial thickness loss of dermis presenting as a shallow open ulcer with a red/pink wound bed, without slough. May also present as an intact or open/ruptured serum-filled blister.

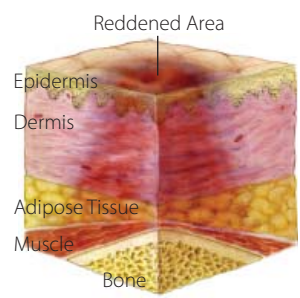


The Medicare Quality Improvement Organization for California
www.hsag.com

PRESSURE ULCERS

Pressure Ulcer Staging Guide

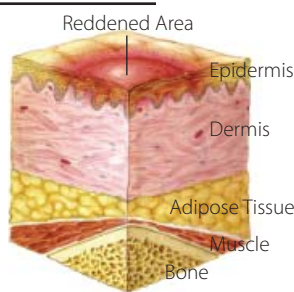
Suspected Deep Tissue Injury:



Purple or maroon localized area of discolored intact skin or blood-filled blister due to damage of underlying soft tissue from pressure and/or shear. The area may be preceded by tissue that is painful, firm, mushy, boggy, warmer, or cooler when compared with adjacent tissue.

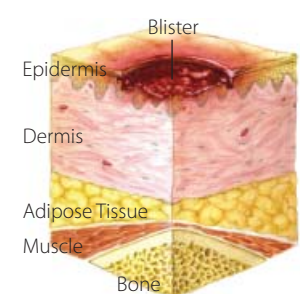
Stage I:

Intact skin with non-blanchable redness of a localized area, usually over a bony prominence. Darkly pigmented skin may not have visible blanching; its color may differ from the surrounding area.



Stage II:

Partial thickness loss of dermis presenting as a shallow open ulcer with a red/pink wound bed, without slough. May also present as an intact or open/ruptured serum-filled blister.

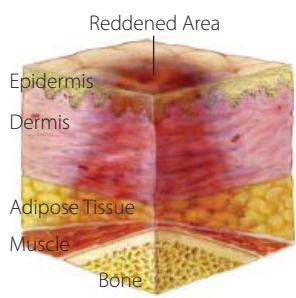


The Medicare Quality Improvement Organization for California
www.hsag.com

PRESSURE ULCERS

Pressure Ulcer Staging Guide

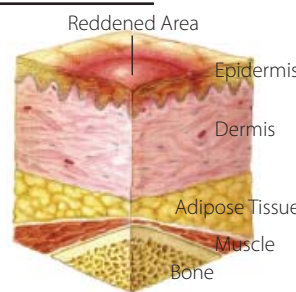
Suspected Deep Tissue Injury:



Purple or maroon localized area of discolored intact skin or blood-filled blister due to damage of underlying soft tissue from pressure and/or shear. The area may be preceded by tissue that is painful, firm, mushy, boggy, warmer, or cooler when compared with adjacent tissue.

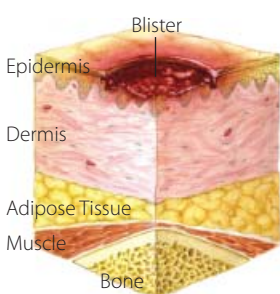
Stage I:

Intact skin with non-blanchable redness of a localized area, usually over a bony prominence. Darkly pigmented skin may not have visible blanching; its color may differ from the surrounding area.



Stage II:

Partial thickness loss of dermis presenting as a shallow open ulcer with a red/pink wound bed, without slough. May also present as an intact or open/ruptured serum-filled blister.

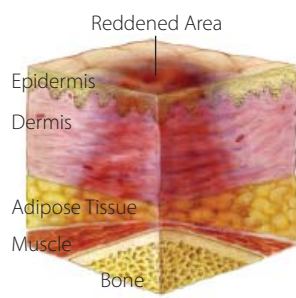


The Medicare Quality Improvement Organization for California
www.hsag.com

PRESSURE ULCERS

Pressure Ulcer Staging Guide

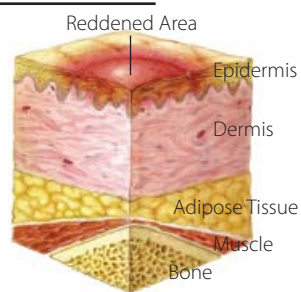
Suspected Deep Tissue Injury:



Purple or maroon localized area of discolored intact skin or blood-filled blister due to damage of underlying soft tissue from pressure and/or shear. The area may be preceded by tissue that is painful, firm, mushy, boggy, warmer, or cooler when compared with adjacent tissue.

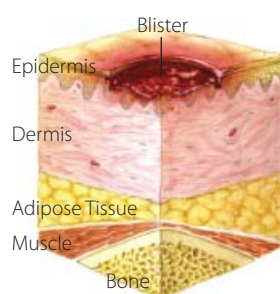
Stage I:

Intact skin with non-blanchable redness of a localized area, usually over a bony prominence. Darkly pigmented skin may not have visible blanching; its color may differ from the surrounding area.



Stage II:

Partial thickness loss of dermis presenting as a shallow open ulcer with a red/pink wound bed, without slough. May also present as an intact or open/ruptured serum-filled blister.

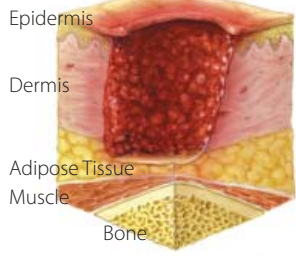


The Medicare Quality Improvement Organization for California
www.hsag.com

PRESSURE ULCERS

Pressure Ulcer Staging Guide (Cont'd)

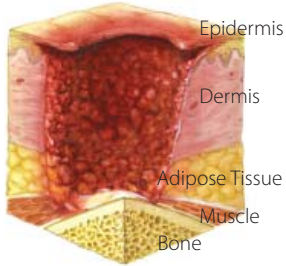
Stage III:



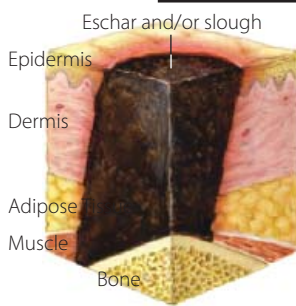
Full thickness tissue loss. Subcutaneous fat may be visible, but bone, tendon, or muscle are not exposed. Slough may be present but does not obscure the depth of tissue loss. May include undermining and tunneling.

Stage IV:

Full thickness tissue loss with exposed bone, tendon, or muscle. Slough or eschar may be present on some parts of the wound bed. Undermining and tunneling may be present.



Unstageable:



Full thickness tissue loss in which the base of the ulcer is covered by slough (yellow, tan, gray, green, or brown) and/or eschar (tan, brown, or black) in the wound bed.



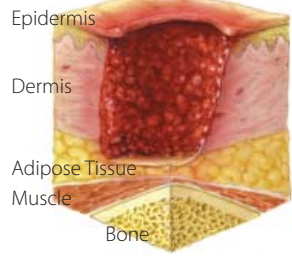
The Medicare Quality Improvement Organization for California
www.hsag.com

This material, created by the Kansas Foundation for Medical Care Inc., was adapted and is distributed by Health Services Advisory Group of California Inc., the Medicare Quality Improvement Organization for California, under contract with the Centers for Medicare & Medicaid Services (CMS), an agency of the U.S. Department of Health and Human Services. The contents presented do not necessarily reflect CMS policy. Publication No. CA-950W-6.2.1-061809-02

PRESSURE ULCERS

Pressure Ulcer Staging Guide (Cont'd)

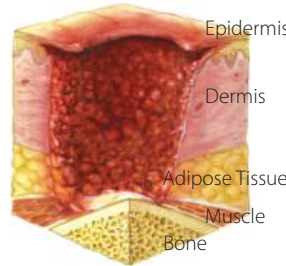
Stage III:



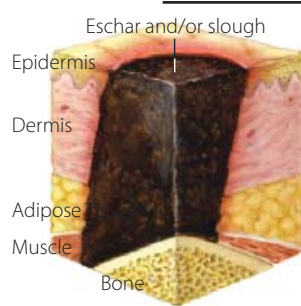
Full thickness tissue loss. Subcutaneous fat may be visible, but bone, tendon, or muscle are not exposed. Slough may be present but does not obscure the depth of tissue loss. May include undermining and tunneling.

Stage IV:

Full thickness tissue loss with exposed bone, tendon, or muscle. Slough or eschar may be present on some parts of the wound bed. Undermining and tunneling may be present.



Unstageable:



Full thickness tissue loss in which the base of the ulcer is covered by slough (yellow, tan, gray, green, or brown) and/or eschar (tan, brown, or black) in the wound bed.



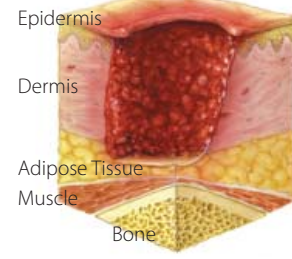
The Medicare Quality Improvement Organization for California
www.hsag.com

This material, created by the Kansas Foundation for Medical Care Inc., was adapted and is distributed by Health Services Advisory Group of California Inc., the Medicare Quality Improvement Organization for California, under contract with the Centers for Medicare & Medicaid Services (CMS), an agency of the U.S. Department of Health and Human Services. The contents presented do not necessarily reflect CMS policy. Publication No. CA-950W-6.2.1-061809-02

PRESSURE ULCERS

Pressure Ulcer Staging Guide (Cont'd)

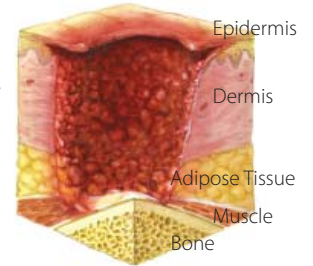
Stage III:



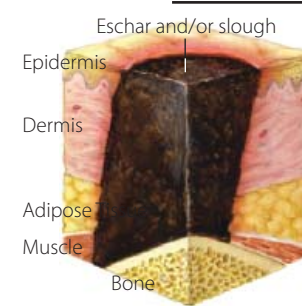
Full thickness tissue loss. Subcutaneous fat may be visible, but bone, tendon, or muscle are not exposed. Slough may be present but does not obscure the depth of tissue loss. May include undermining and tunneling.

Stage IV:

Full thickness tissue loss with exposed bone, tendon, or muscle. Slough or eschar may be present on some parts of the wound bed. Undermining and tunneling may be present.



Unstageable:



Full thickness tissue loss in which the base of the ulcer is covered by slough (yellow, tan, gray, green, or brown) and/or eschar (tan, brown, or black) in the wound bed.



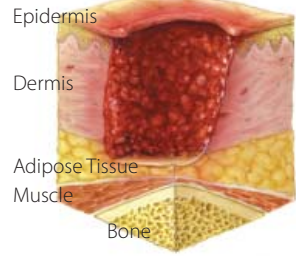
The Medicare Quality Improvement Organization for California
www.hsag.com

This material, created by the Kansas Foundation for Medical Care Inc., was adapted and is distributed by Health Services Advisory Group of California Inc., the Medicare Quality Improvement Organization for California, under contract with the Centers for Medicare & Medicaid Services (CMS), an agency of the U.S. Department of Health and Human Services. The contents presented do not necessarily reflect CMS policy. Publication No. CA-950W-6.2.1-061809-02

PRESSURE ULCERS

Pressure Ulcer Staging Guide (Cont'd)

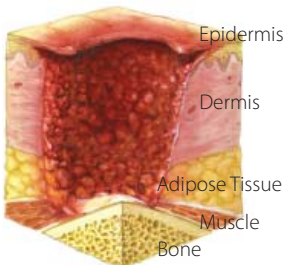
Stage III:



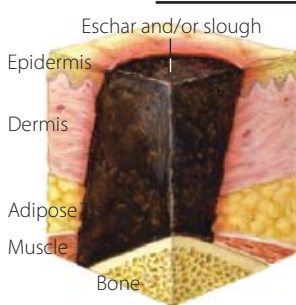
Full thickness tissue loss. Subcutaneous fat may be visible, but bone, tendon, or muscle are not exposed. Slough may be present but does not obscure the depth of tissue loss. May include undermining and tunneling.

Stage IV:

Full thickness tissue loss with exposed bone, tendon, or muscle. Slough or eschar may be present on some parts of the wound bed. Undermining and tunneling may be present.



Unstageable:



Full thickness tissue loss in which the base of the ulcer is covered by slough (yellow, tan, gray, green, or brown) and/or eschar (tan, brown, or black) in the wound bed.



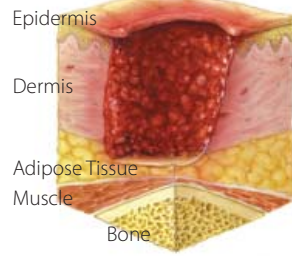
The Medicare Quality Improvement Organization for California
www.hsag.com

This material, created by the Kansas Foundation for Medical Care Inc., was adapted and is distributed by Health Services Advisory Group of California Inc., the Medicare Quality Improvement Organization for California, under contract with the Centers for Medicare & Medicaid Services (CMS), an agency of the U.S. Department of Health and Human Services. The contents presented do not necessarily reflect CMS policy. Publication No. CA-950W-6.2.1-061809-02

PRESSURE ULCERS

Pressure Ulcer Staging Guide (Cont'd)

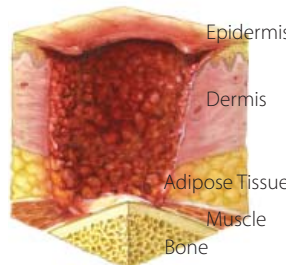
Stage III:



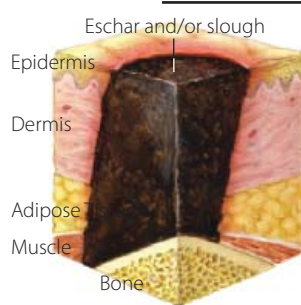
Full thickness tissue loss. Subcutaneous fat may be visible, but bone, tendon, or muscle are not exposed. Slough may be present but does not obscure the depth of tissue loss. May include undermining and tunneling.

Stage IV:

Full thickness tissue loss with exposed bone, tendon, or muscle. Slough or eschar may be present on some parts of the wound bed. Undermining and tunneling may be present.



Unstageable:



Full thickness tissue loss in which the base of the ulcer is covered by slough (yellow, tan, gray, green, or brown) and/or eschar (tan, brown, or black) in the wound bed.



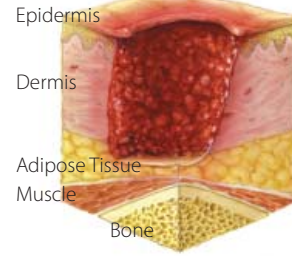
The Medicare Quality Improvement Organization for California
www.hsag.com

This material, created by the Kansas Foundation for Medical Care Inc., was adapted and is distributed by Health Services Advisory Group of California Inc., the Medicare Quality Improvement Organization for California, under contract with the Centers for Medicare & Medicaid Services (CMS), an agency of the U.S. Department of Health and Human Services. The contents presented do not necessarily reflect CMS policy. Publication No. CA-950W-6.2.1-061809-02

PRESSURE ULCERS

Pressure Ulcer Staging Guide (Cont'd)

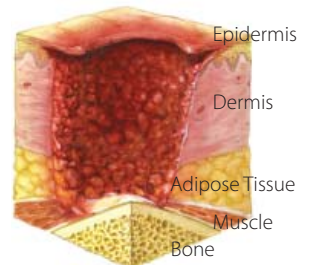
Stage III:



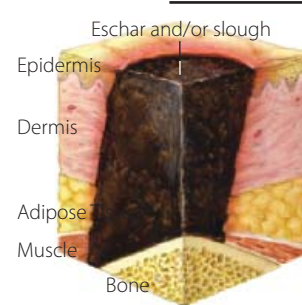
Full thickness tissue loss. Subcutaneous fat may be visible, but bone, tendon, or muscle are not exposed. Slough may be present but does not obscure the depth of tissue loss. May include undermining and tunneling.

Stage IV:

Full thickness tissue loss with exposed bone, tendon, or muscle. Slough or eschar may be present on some parts of the wound bed. Undermining and tunneling may be present.



Unstageable:



Full thickness tissue loss in which the base of the ulcer is covered by slough (yellow, tan, gray, green, or brown) and/or eschar (tan, brown, or black) in the wound bed.



The Medicare Quality Improvement Organization for California
www.hsag.com

This material, created by the Kansas Foundation for Medical Care Inc., was adapted and is distributed by Health Services Advisory Group of California Inc., the Medicare Quality Improvement Organization for California, under contract with the Centers for Medicare & Medicaid Services (CMS), an agency of the U.S. Department of Health and Human Services. The contents presented do not necessarily reflect CMS policy. Publication No. CA-950W-6.2.1-061809-02